

Clinical Case Study

UROcellz

Clinical History

Patient first experienced Erectile Dysfunction when he was taking anti-depressant medication in 2010. Although, he discontinued taking the medication, his Erectile Dysfunction persisted and he started taking Viagra to help. Patient took Viagra for 3 months and admitted that the oral medication did help but he was unhappy with the results since his erections did not

last. Patient has a decrease in testosterone level. Patient is a smoker and discussed its association with vascular disorders and recommended that he try to quit.

OVERVIEW

PATIENT AGE

46

DIAGNOSIS

ERECTILE DYSFUNCTION

CAUSE

ANTI-DEPRESSANTS

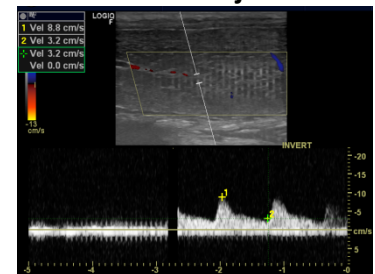
Management & Outcomes

Initial visit - Penile Doppler PSV 8.8 cm/s with 0.1cc of Trimix #9. ProFlo amniotic fluid (2 mL) (Vivex Biomedical Inc., Miami, FL) mixed with 25 mL of PRP was injected bilaterally into the corpora.

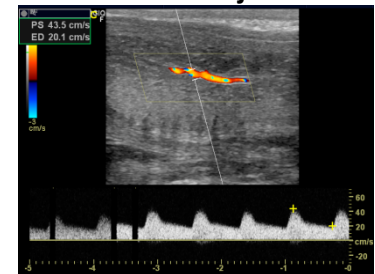One month follow-up - Patient reports noted improvement with erections that are consistent. Penile Doppler PSV 43.5 cm/s with 0.1cc of Trimix #9. Patient received another injection (2 mL ProFlo with 21 mL of PRP).

Three month follow-up - Patient states he is now able to have erections without oral medications and that he is now able to have repeated intercourse in one session which was something he was unable to achieve for a few years.

Pre ProFlo Injection



Post ProFlo Injection



FLO--- 1 APPLICATION----ABILITY TO HAVE CONSISTENT ERECTIONS

2 APPLICATION-- -ABILITY TO HAVE REPEATED INTERCOURSE WITHOUT ORAL MEDS