

Clinical Case Study

UROcellz

Clinical History

Patient is an African American man with a past medical history of hypertension and prostate cancer, status post prostatectomy, complaining of soft, non-sustained erection of one-year duration. Currently, patient cannot obtain erections at all. Patient had tried sildenafil (Viagra) without any improvement. Patient denies other urologic issues.

OVERVIEW

PATIENT AGE

66

DIAGNOSIS

ERECTILE DYSFUNCTION

CAUSE

POST RADICAL PROSTATECTOMY

Management & Outcomes

Initial visit - Penile Doppler PSV 12.9, 70% rigidity with 0.1cc of Trimix #9. ProFlo amniotic fluid (1 mL) (Vivex Biomedical Inc., Miami, FL) in sterile saline (4 mL) was injected into plaque mid-shaft and bilateral corpora.

Two weeks after initial visit, patient was still complaining of erectile dysfunction with no change.

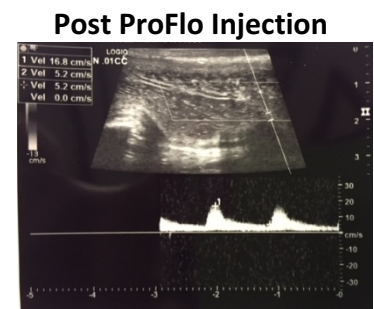
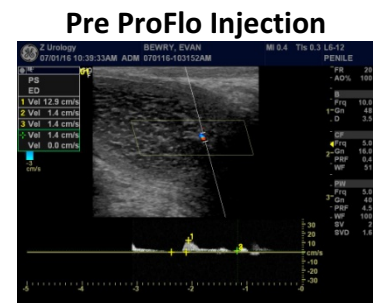
One month follow-up - patient was still complaining of erectile dysfunction with no change since last visit. Penile Doppler PSV was 14.6 cm/s with 0.1cc of Trimix #9.

Two-month follow-up - patient stated he was now able to achieve

occasional morning erections with no oral or injectable medications. Patient admits he was unable to achieve erections prior to amniotic fluid injection. Penile Doppler PSV 15.0 cm/s with 0.1cc of Trimix #9.

2 months after receiving the ProFlo injection, patient was extremely excited and was able to obtain erections. In addition, he also was able to use Viagra to achieve maximum results for intercourse.

Three - month follow up - patient was still able to have erections but continued with Viagra for increase rigidity for intercourse. (PSV=16.8 cm/s).



PROFLO---1 APPLICATION ---NO CHANGE--2 MONTHS---ABILITY TO HAVE ERECTIONS

<http://urocellz.com/wp-content/uploads/2017/05/Mr-EB.mov>